

Buerger's Disease: A Bench-to-Bedside Review

Mohammad-Hadi Saeed Modagheh¹, Shirin Saberianpour^{1,*}

¹Vascular and Endovascular Surgery Research Center, Mashhad University of Medical Sciences, Mashhad, Iran

Corresponding author: Dr. Shirin Saberianpour

Vascular and Endovascular Surgery Research Center, Mashhad University of Medical Sciences, Mashhad, Iran

Email: saberianpoursh@mums.ac.ir; Tel/Fax: +98 51 38047201; <https://orcid.org/0000-0001-5354-3939>

Received: November, 27, 2020 Accepted: January, 10, 2021

Abstract

Buerger's disease or thromboangiitis obliterans is a non-atherosclerotic vascular disease that causes inflammation of the blood vessels and arterial occlusion in the extremities, resulting in impaired distal perfusion. Tobacco use is the main etiologic factor and is responsible for the progression and recurrence of the symptoms. Also, several contributing factors to the pathogenesis of the disease have been suggested, such as immunologic mechanisms and genetic predisposition. The disease is more prevalent in the Middle East and the Far East than in North America and Western Europe. Patients are often young male smokers, who may present with burning pain and paresthesia, cold sensitivity, purple discoloration, superficial thrombophlebitis, intermittent claudication, ischemic rest pain, ulcer, or gangrene. The diagnosis is based on the clinical criteria, such as Shionoya, Olin, Papa, and Mills criteria. Smoking cessation is the only effective treatment for pain relief, blood flow improvement, and limb salvage. However, additional therapeutic options have been proposed, such as sympathectomy, prostaglandin infusion, endovascular angioplasty, and surgical revascularization. If treatment measures fail, amputation may be inevitable.

Keywords: Buerger's disease, Thromboangiitis obliterans, Vascular disease

Introduction

Buerger's disease also known as thromboangiitis obliterans, is a non-atherosclerotic obstructive disorder, involving small- to medium-sized arteries and veins of the upper and lower limbs [1]. The disorder was first described in 1879 by Felix von Winiwarter [2]. A detailed description of the condition was reported by Leo Buerger later in 1908 [3]. Although Buerger's disease has been first described over a century ago, the condition remains poorly understood. This review aims to provide an overview of the current basic and clinical knowledge about Buerger's disease.

Epidemiology

Although the disease typically occurs in young male smokers, the incidence among women has relatively increased during the last few decades. Buerger's disease has a global distribution [4]. However, the disease is more prevalent in the Middle East and the Far East than in North America and Western Europe [4]. The prevalence of the disease among all in-hospital-treated patients with peripheral arterial disease has been reported as follows: Western European countries: 0.5 to 5.6%,

India: 45 to 63%, Japan and Korea: 16 to 66%, and Ashkenazi Jews: 80%. In addition, Buerger's disease usually occurs in patients with low socioeconomic status [5, 6].

Risk factors

Tobacco exposure is proved to be an essential factor for the onset and progression of Buerger's disease [7]. Although smoking is the most common risk factor, the disease may also be caused by chewing tobacco or marijuana consumption [8]. In general, there is a close relationship between tobacco use and the onset, clinical manifestations, and recurrence of Buerger's disease. Thus, tobacco is recognized as a major risk factor [9]. Other important risk factors include male gender, race, and age between 20 and 45 [10, 11].

Immunologic mechanisms

Many researchers have examined specific pathological mechanisms in Buerger's disease. Inflammatory cells such as CD3+ T cells, CD4 cells, and CD20 B cells respond to the elastic layer of vessels involved in Buerger's disease in the subacute stage [12]. Small abscesses are observed in the acute

stage of Buerger's disease, which can be associated with acute inflammation in the intima and thrombus formation [11]. The chronic stage usually includes obstruction and is characterized by prominent arterial and perivascular fibrosis. In general, the structure of the vascular wall and the internal elastic lamina, unlike atherosclerosis and other types of vasculitis, are not damaged in Buerger's disease [13]. Endothelial cells seem to play a crucial role in the initiation and persistence of the inflammatory response [14]. A further expression of adhesive molecules, such as VCAM-1, ICAM-1, and selectin on the endothelial cell surface has been confirmed [15]. Some researchers believe that Buerger's disease is an endarteritis caused by some antigens. CD8+ T cells may be involved in the onset of the disease [15]. The activity of CD4+ T cells is at least as evident as CD8+ T cells during the progression of Buerger's lesions [16]. CD68+ macrophages and S-100-positive dendritic cells can be seen in intima layer in acute and subacute stages of Buerger's disease [17]. Immunoglobulins and complement factors are present in the elastic layer in the acute or subacute stage of the disease [17].

Genetic predisposition

Genetic analysis of patients with Buerger's disease showed that the prevalence of HLA A-9 and HLA B-5 is higher and the prevalence of HLA-B12 is lower in patients with Buerger's disease than in healthy individuals [18, 19]. Variations in the expression of the HLA genes occur in Buerger's disease and this change in gene expression varies in different racial populations [20, 21]. According to a study conducted in Mashhad, HLA class I and II were associated with Buerger's disease [21]. The MyD88 signaling pathway is one of the most important innate safety signaling pathways in Toll-like receptors (TLRs). A study by Chen et al. indicated that rs7744 single nucleotide polymorphism (SNP) in the MyD88 gene was significantly lower in Japanese patients with Buerger's disease than in the healthy group [22]. Besides, the occurrence of endothelial nitric oxide synthase (eNOS) gene on position 894 is related to a reduced incidence of Buerger's disease. It was, therefore, suggested that the eNOS gene polymorphism of the 894G → T gene polymorphism plays a protective role against the Buerger's disease development. Also, Chen et al. reported that the frequency of genotype CD14 TT, HLA-DRB1 1501, and HLA-DPB1 0501 was significantly higher in patients with Buerger's disease than in healthy individuals [23]. A case-

control study to identify genetic factors involved in the development of Buerger's disease demonstrated that SNPs rs376511 in IL17RC and rs7632505 in SEMA5B are associated with a significant risk of developing Buerger's disease. It was shown in a study, performed in China, that Buerger's disease is controlled by genes involved in innate and acquired immunity [3].

Histopathology

A biopsy is rarely indicated, and clinical assessment is usually sufficient to diagnose Buerger's disease. Histological specimens can be obtained from amputated limbs or a superficial inflamed vein in patients with Buerger's disease [24]. Biopsy from an ischemic limb is not recommended due to the risk of causing chronic non-healing ulcers [25]. The pathological findings of specimens from Buerger's patients are different from those of other vascular patients [26]. Thus, Buerger's disease can be differentiated from atherosclerosis, idiopathic arterial thrombosis, or vasculitis. The pathological stages of Buerger's disease can be categorized into acute, intermediate or subacute, and chronic stages [27]. Acute phase lesions include highly-cellular occlusive thrombus with microabscess, and vascular wall inflammation involving polymorphonuclear leukocytes, and multinucleated giant cells. Progressive organization of the occlusive thrombus and partial recanalization can be seen in the intermediate or subacute phase [17]. In the chronic phase, thrombus organization and extensive recanalization, as well as perivascular fibrosis are observed [28].

Diagnostic criteria

The diagnosis of Buerger's disease is mainly based on clinical criteria. For instance, the Shionoya criteria include the history of smoking, the onset of disease before the age of 50, infrapopliteal artery disease, upper extremity involvement or migratory thrombophlebitis, and no risk factors for atherosclerosis other than smoking [29]. There is no specific diagnostic test and serological marker for definitive diagnosis of Buerger's disease [29]. In addition to Shionoya's diagnostic criteria, Olin [30], Papa [31], and Mills [32] have proposed diagnostic criteria for Buerger's disease. There are differences in defining the diagnosis for Buerger's disease by these criteria. For instance, the age at onset is less than 50 years in Shionoya's diagnostic criteria, as opposed to less than 45 years in Olin's and in Mill's diagnostic criteria [30, 32].

Clinical presentations

Patients usually present with signs and symptoms of distal extremity ischemia [33]. The disease progression can be observed over time with the involvement of more proximal arteries. However, the involvement of the large arteries is unusual [34]. Multiple limb involvement is common, and more than one limb is usually involved [29]. Early findings include cold sensitivity and sensory disturbance such as paresthesia. Sometimes, migratory superficial thrombophlebitis can be an early sign. Also, the disease may be manifested with burning pain in the feet and hands, Raynaud phenomenon, purple discoloration, intermittent claudication of the foot and calf or hand and arm. As the disease progresses, rest pain, ischemic ulcers, and gangrene develop (Figure 1). The vascular examination may reveal absent distal pulses and abnormal Allen's test [35]. Rarely, cerebral, coronary, or visceral arteries can be involved, leading to the development of atypical symptoms [36].

Diagnostic evaluation

As discussed before, the diagnosis is mainly based on the diagnostic criteria. In addition to a detailed history and physical examination, laboratory tests and imaging studies are beneficial in confirming the diagnosis, determining the severity of the disease, and excluding the differential diagnoses. Digital plethysmography and ankle-brachial index measurement are recommended. In arteriography, segmental distal occlusions, normal proximal arteries, corkscrew collaterals, and absence of arterial wall calcification are suggestive of Buerger's disease (Figure 2). Duplex ultrasound can reveal distal occlusive disease and exclude atherosclerosis. Additionally, echocardiography and abdominal ultrasonography may be done to exclude the proximal source of emboli. Several laboratory tests are also suggested, such as inflammatory markers and autoantibodies to rule out connective tissue disease, and coagulation profile for the exclusion of thrombophilia [32, 37, 38].

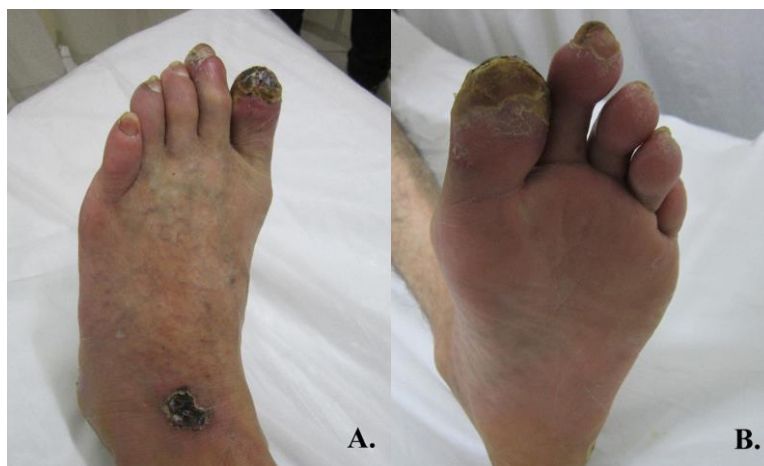

Figure 1. Ischemic ulceration of the toe and purple discoloration (A, and B)

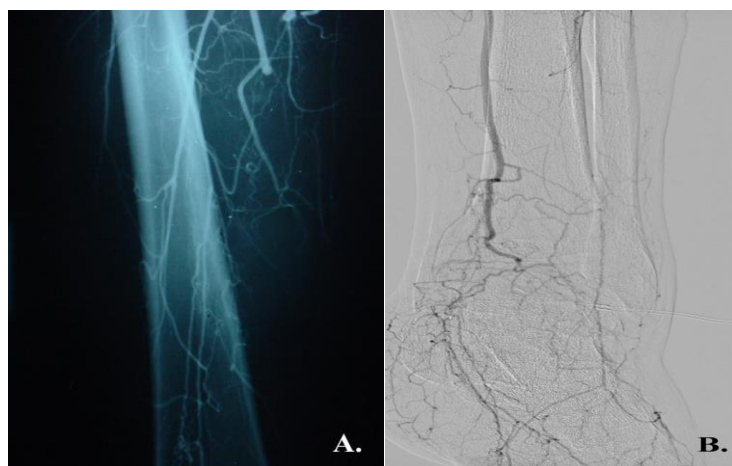


Figure 2. Abrupt arterial occlusion with corkscrew collaterals (A, and B)

Buerger's disease in Iran

In a study in Mashhad, Modagheh et al. examined 225 patients with Buerger's disease from 2000 to 2010. During the study period, patients' clinical characteristics, family history, and tobacco use were reviewed. The patients included 222 males (98.7%) and 3 females (1.3%). The mean age of patients was 40.7 years, and 88.9% of them were smokers. The clinical manifestations were chronic ulcer (80%), claudication (63.6%), Rest pain (60%), finger gangrene (57.8%), cold sensitivity (44%), purple discoloration (40.4%), paresthesia (28.4%) and migratory thrombophlebitis (18.7%). Both upper and lower limbs were involved in 98 patients (43.6%). Seventeen patients (7.6%) with Buerger's disease received prostaglandin infusion. A total of 150 sympathectomy procedures were performed, while surgical bypass was done in only 4 patients (1.8%). Also, 113 (50.2%) and 41 (18.4%) patients underwent minor and major amputations, respectively [6].

Salimi et al. conducted a study on 116 male smoker patients in Tehran from 1997 to 2002 to determine the clinical course of Buerger's disease. All hospitalized patients were diagnosed according to Shionoya clinical criteria. The patients' involvement was found to be as follows: Lower limb involvement in 102 patients (87.9%), upper limb involvement in 3 patients (2.6%), and both lower and upper limbs involvement in 11 patients (9.5%). The most common reasons for hospitalization included ischemic ulcers (90.5%), claudication (87.9%), paresthesia (75.9%), rest pain (66.4%), gangrene (60.3%), Raynaud's phenomenon (23.3%), and thrombophlebitis (9.5%) [39].

An Iranian Scoring System for Diagnosing Buerger's Disease by Ramin et al. suggested a model, involving patient's age, sex, smoking, Raynaud's phenomenon, abnormal proximal Doppler, and absence of diabetes mellitus and hyperlipidemia, as diagnostic criteria for Buerger's disease. According to this study, the sensitivity and specificity of the criteria were respectively 95.1% and 78.7% [40].

Another study by Tavakoli et al. on 198 Buerger's patients during a 10-year period (1996-2006) in Tehran showed that all cases were male smokers, and had a mean age of 40.5 years. The range of clinical symptoms included 91.4% lower limb involvement, 2% upper limb involvement, and 6.6% both lower and upper limb involvement. Patients underwent sympathectomy, amputation and bypass surgery [41].

In a study in northeast of Iran, migratory phlebitis was detected as an early alarming sign for the onset of Buerger's disease [42]. In addition, other studies have been performed in Mashhad on various aspects of the Buerger's disease such as the effect of HLA patterns on the disease pathogenesis [21], the role of endovascular therapy in the management of Buerger's patients with critical limb ischemia [43], and the association of immunological factors with the disease severity [12].

Treatment

Smoking cessation is the basis of treatment for Buerger's disease. However, when ulcer or gangrene occurs, smoking cessation alone may not be enough to relieve the pain and improve wound healing. [44]. The therapeutic goals include improving distal flow, alleviating pain, healing the ulcer, preventing amputation, and treating concomitant infections (Table 1) [45-47]. Oral medications such as antiplatelets, calcium channel blockers, folic acid supplements, and analgesics are suggested to be prescribed [27, 48]. When there is a superimposed infection, administration of antibiotics and wound care is of utmost importance. Therapeutic measures such as sympathectomy, prostaglandin infusion, surgical bypass, and endovascular therapy are considered for patients with ischemic rest pain or tissue loss [49]. Often, bypass surgery is not feasible, because a distal target vessel is usually not available [50]. Sympathectomy is effective temporarily, but symptoms usually recur after weeks or months. [51, 52]. Prostaglandin analogs have shown promising results. However, a relatively prolonged hospital stay is necessary for the infusion of prostaglandins. In patients with critical limb ischemia, percutaneous angioplasty can be considered an alternative to sympathectomy and prostaglandin infusion for restoration of distal blood flow and limb salvage [43]. A summary of therapeutic methods (other than smoking cessation) for the management of Buerger's disease is presented in Table 2.

Table1. Therapeutic goals for Buerger's disease

Therapeutic goals for Buerger's disease
Improving arterial blood flow
Alleviating ischemic pain
Treating concomitant infections
Facilitating wound healing
Preventing limb amputation

Table2. A summary of treatments for Buerger's disease

Type of therapy	Subtype of therapy	Advantage	Reference
Surgical therapy	Lumbar or thoracic sympathectomy	Increase in blood flow	[53]
Endovascular therapy	Balloon angioplasty	A technically feasible and effective option	[43]
Endovascular therapy	Balloon angioplasty	A potential option for both lower and upper limb involvement	[45]
Surgical therapy	Bypass surgery	If technically feasible, long-term patency is satisfactory in patients who can stop smoking	[50]
Surgical therapy	Bypass surgery	Plays a role in cases of previous failed endovascular treatment or extensive tissue loss	[54]
Pharmacological therapy	Vasodilators (iloprost, bosentan, sildenafil, alprostadil)	Early treatment with vasodilators may prevent amputation	[55]
Pharmacological therapy	Aspirin, prostaglandin analogue, folic acid, cilostazol, clopidogrel and pentoxifylline	Intravenous iloprost is more effective than aspirin for relieving rest pain and healing ischemic ulcers	[48]
Cell therapy	Intravenous allogeneic mesenchymal stromal cells	An effective treatment for TAO, warranting further studies to compare this approach with the more conventionally used intramuscular MSC administration and other cell-based therapies	[56]
Cell Therapy	Stem cell therapy using Umbilical Cord Blood-Derived Multipotent Stem Cells	Human UCB-derived MSC transplantation may be a new and useful therapeutic for Buerger's disease and similar ischemic diseases	[57]
Cell therapy	Autologous bone marrow mononuclear cell	A relatively safe procedure with no demonstrable side effects at 6 months.	[58]
Cell therapy	Autologous adipose tissue-derived mesenchymal stem cell	Autologous AdMSC can be an effective alternative treatment for Buerger's disease.	[59]
Gene therapy	HGF plasmid DNA	Hepatocyte growth factor gene therapy is safe and effective for critical limb ischemia in patients with Buerger's disease	[60]
Gene therapy	Intramuscular phVEGF165 gene	A novel therapy for patients with advanced Buerger's disease who are unresponsive to standard medical or surgical treatment methods	[61]

Conclusion

Although Buerger's disease has been known and diagnosed for more than a century, the mechanism of the pathogenesis and progression, as well as specific diagnostic markers have not yet been fully identified. Therefore, this disease can be diagnosed only by experienced specialists familiar with the diagnostic criteria. On the other hand, smoking cessation is the cornerstone of the treatment. However, there is no single therapy for this disease. Sometimes, patients may not be able or willing to stop smoking. In cases in whom critical limb ischemia occurs, endovascular interventions have shown promising results for limb salvage.

Acknowledgment

The authors wish to thank the personnel of Vascular and Endovascular Surgery Research Center of Mashhad University of Medical Sciences.

Author contribution

Both authors contributed equally and approved the final version of the manuscript.

Conflict of Interest

The authors declare no conflicts of interest.

Ethical declaration

Not applicable

Funding source

There was no source of funding.

References

- Goiriz-Valdés R, Fernández-Herrera J. [Buerger's disease (thromboangiitis obliterans)]. *Actas Dermosifiliogr.* 2005; 96(9):553-62.
- Mills JL, Taylor Jr LM, Porter JM. Buerger's disease in the modern era. *Am J Surg.* 1987; 154(1):123-9.
- Shi Z-F, Fang Q-B, Limu S, Jiareke T, Ge X-H. Association between Three SNPs and thromboangiitis

- obliterans in xinjiang uyghur population. *Genet Test Mol Biomarkers*. 2016; 20(2):55-62.
4. Le Joncour A, Soudet S, Dupont A, Espitia O, Koskas F, Cluzel P, et al. Long-Term Outcome and Prognostic Factors of Complications in Thromboangiitis Obliterans (Buerger's Disease): A Multicenter Study of 224 Patients. *J Am Heart Assoc*. 2018; 7(23):e010677.
 5. Ohta T, Ishioashi H, Hosaka M, Sugimoto I. Clinical and social consequences of Buerger disease. *J Vasc Surg*. 2004; 39(1):176-80.
 6. Modaghegh M-HS, Kazemzadeh GH, Ravari H, Johari HG, Barzanuni A. Buerger's disease in the northeast of Iran: Epidemiology and clinical features. *Vascular*. 2015; 23(5):519-24.
 7. Piazza G, Creager MA. Thromboangiitis obliterans. *Circulation*. 2010; 121(16):1858-61.
 8. Alamdari DH, Ravari H, Tavallaie S, Fazeli B. Oxidative and antioxidative pathways might contribute to thromboangiitis obliterans pathophysiology. *Vascular*. 2014; 22(1):46-50.
 9. Rahman M, Fukui T. Bidi smoking and health. *Public Health*. 2000; 114(2):123-7.
 10. Rivera-Chavarría IJ, Brenes-Gutiérrez JD. Thromboangiitis obliterans (Buerger's disease). *Ann Med Surg (Lond)*. 2016; 7:79-82.
 11. Klein-Weigel PF, Richter JG. Thromboangiitis obliterans (Buerger's disease). *Vasa*. 2014; 43(5):337-46.
 12. Ehteshamfar SM, Afshari JT, Modaghegh M-HS, Mahmoudi M, Kazemzadeh GH, Kermani FS. Humoral and cellular immune response to Buerger's disease. *Vascular*. 2020; 28(4):457-64.
 13. Ren B, Duan M, Liu Z, Xu D, Liu D, Zhang J, et al. Fibrinogen, Neutrophil-to-Lymphocyte Rate and Platelet-to-Neutrophil Rate as Novel Acute Phase Indicators in Patients with Thromboangiitis Obliterans. *Ann Vasc Surg*. 2020; 65:137-44.
 14. Mousazadeh B, Sharebani H, Taheri H, Valizedeh N, Fazeli B. Unexpected inflammation in the sympathetic ganglia in thromboangiitis obliterans: more likely sterile or infectious induced inflammation? *Clin Mol Allergy*. 2019; 17(1):10.
 15. Sharebani H, Fazeli B, Maniscalco R, Ligi D, Mannello F. The Imbalance among Oxidative Biomarkers and Antioxidant Defense Systems in Thromboangiitis Obliterans (Winiwarer-Buerger Disease). *J Clin Med*. 2020; 9(4):1036.
 16. Fazeli B, Keramat S, Assadi L, Taheri H. Angiogenesis induction in Buerger's disease: a disease management double-edged sword? *Orphanet J Rare Dis*. 2019; 14(1):1-6.
 17. Kobayashi M, Sugimoto M, Komori K. Endarteritis obliterans in the pathogenesis of Buerger's disease from the pathological and immunohistochemical points of view. *Circ J*. 2014; 78(12):2819-26.
 18. Shapouri-Moghaddam A, Modaghegh M-HS, reza Rahimi H, Ehteshamfar S-M, Afshari JT. Molecular mechanisms regulating immune responses in thromboangiitis obliterans: A comprehensive review. *Iran J Basic Med Sci*. 2019; 22(3):215-24.
 19. Zervas J, Vayopoulos G, Konstantopoulos K, Zervas C, Liapis C, Kaklamanis P, et al. HLA antigens in Burger's disease. *Clin Rheumatol*. 1991; 10(4):434-6.
 20. Braun WE. HLA and disease, CRC Press, Boca Raton, FL (1979).
 21. Shapouri-Moghaddam A, Mohammadi M, Rahimi HR, Esmaeili H, Mahmoudi M, Modaghegh M-HS, et al. The Association of HLA-A, B and DRB1 with Buerger's Disease. *Rep Biochem Mol Biol*. 2019; 8(2):153-60.
 22. Chen Z, Nakajima T, Inoue Y, Kudo T, Jibiki M, Iwai T, et al. A single nucleotide polymorphism in the 3'-untranslated region of MyD88 gene is associated with Buerger disease but not with Takayasu arteritis in Japanese. *J Hum Genet* 2011; 56(7):545-7.
 23. Chen Z, Takahashi M, Naruse T, Nakajima T, Chen Y-W, Inoue Y, et al. Synergistic contribution of CD14 and HLA loci in the susceptibility to Buerger disease. *Hum Genet*. 2007; 122(3-4):367-72.
 24. Kobayashi M, Nishikimi N, Komori K. Current pathological and clinical aspects of Buerger's disease in Japan. *Ann Vasc Surg*. 2006; 20(1):148-56.
 25. Leithäuser B, Langheinrich AC, Rau WS, Tillmanns H, Matthias FR. A 22-year-old woman with lower limb arteriopathy. Buerger's disease, or methamphetamine-or cannabis-induced arteritis? *Heart Vessels*. 2005; 20(1):39-43.
 26. Kiruba K, Koranga H, Ramaraj C, Takalkar AA. Role of risk factors, clinical features and treatment modality in early detection and management of Buerger's disease: a study from tertiary care centre Pondicherry. *Int Surg J*. 2020; 7(6):1718-22.
 27. Modaghegh MHS, Ravari H, Haghghi MZ, Rajabnejad Ao. Effect of folic acid therapy on homocysteine level in patients with atherosclerosis or Buerger's disease and in healthy individuals: a clinical trial. *Electron Physician*. 2016; 8(10):3138-43.
 28. Buerger L. Landmark Publication from The American Journal of the Medical Sciences: Thrombo-Angiitis Obliterans: A Study of the Vascular Lesions Leading to Presenile Spontaneous Gangrene1. *Am J M Sc*. 2009; 337(4):274-84.
 29. Shionoya S. Diagnostic criteria of Buerger's disease. *Int J Cardiol*. 1998; 66:S243-S5.
 30. Olin JW. Thromboangiitis obliterans (Buerger's disease). *Peripheral Arterial Disease: Springer*; 2003. p. 303-18.
 31. Papa MZ, Rabi I, Adar R. A point scoring system for the clinical diagnosis of B uerger's disease. *Eur J Vasc Endovasc Surg*. 1996; 11(3):335-9.
 32. Mills Sr JL, editor. Buerger's disease in the 21st century: diagnosis, clinical features, and therapy. *Seminars in vascular surgery*; 2003: Elsevier.
 33. Dimmick S, Goh A, Cauzza E, Steinbach L, Baumgartner I, Stauffer E, et al. Imaging appearances of Buerger's disease complications in the upper and lower limbs. *Clin Radiol*. 2012; 67(12):1207-11.
 34. Klein-Weigel P, Volz T, Gutsche-Petrak B, Boehnlein J, Bohlen A. Immunoabsorption in Buerger's disease (thromboangiitis obliterans): a promising therapeutic option: results of a consecutive patient cohort treated in clinical routine care. *Lupus Open Access*. 2016; 1(2):1000114.
 35. Hirsch AT, Haskal ZJ, Hertzner NR, Bakal CW, Creager MA, Halperin JL, et al. ACC/AHA 2005 practice guidelines for the management of patients with peripheral arterial disease (lower extremity, renal,

- mesenteric, and abdominal aortic) a collaborative report from the American Association for Vascular Surgery/Society for Vascular Surgery,* Society for Cardiovascular Angiography and Interventions, Society for Vascular Medicine and Biology, Society of Interventional Radiology, and the ACC/AHA Task Force on Practice Guidelines (writing committee to develop guidelines for the management of patients with peripheral arterial disease): endorsed by the American Association of Cardiovascular and Pulmonary Rehabilitation; National Heart, Lung, and Blood Institute; Society for Vascular Nursing; TransAtlantic Inter-Society Consensus; and Vascular Disease Foundation. *Circulation*. 2006; 113(11):e463-654.
36. Aszalos C, Dongó E, Farkas Z, Kollár A, Magyar P, Várallyay G, et al. Cerebral manifestations of thromboangiitis obliterans. Case report. *Orv Hetil*. 2016; 157(30):1207-11.
37. Adar R, Papa M, Schneiderman J. Thromboangiitis obliterans: an old disease in need of a new look. *Int J Cardiol*. 2000; 75:S167-S70.
38. Çalgüneri M, Öztürk MA, Ay H, Murat Arsava E, Atinok D, Ertenli I, et al. Buerger's Disease with Multisystem Involvement. *Angiology*. 2004; 55(3):325-8.
39. Salimi J, Tavakkoli H, Salimzadeh A, Ghadimi H, Habibi G, Masoumi A-A. Clinical characteristics of Buerger's disease in Iran. *J Coll Physicians Surg Pak*. 2008; 18(8):502-5.
40. Ramin M, Salimi J, Meysamie A. An Iranian scoring system for diagnosing Buerger's disease. *Acta Medica Iranica*. 2014; 52(1):60-5.
41. Tavakoli H, Rezaii J, Esfandiari K, Salimi J, Rashidi A. Buerger's disease: a 10-year experience in Tehran, Iran. *Clin Rheumatol*. 2008; 27(3):369-71.
42. Fazeli B, Modaghegh H, Ravrai H, Kazemzadeh G. Thrombophlebitis migrans as a footprint of Buerger's disease: a prospective-descriptive study in north-east of Iran. *Clin Rheumatol*. 2008; 27(1):55-7.
43. Modaghegh M-HS, Hafezi S. Endovascular treatment of thromboangiitis obliterans (Buerger's disease). *Vasc Endovascular Surg*. 2018; 52(2):124-30.
44. Kaltari DK. Clinical study Evaluation and Management of Buerger's Disease (Thromboangiitis Obliterans): RGUHS Digital Repository; 2006.
45. Kawarada O, Kume T, Ayabe S, Nakaya T, Nakai M, Nishimura K, et al. Endovascular therapy outcomes and intravascular ultrasound findings in thromboangiitis obliterans (Buerger's disease). *J Endovasc Ther*. 2017; 24(4):504-15.
46. Boda Z, Udvardy M, Rázsó K, Farkas K, Tóth J, Jámor L, et al. Stem cell therapy: a promising and prospective approach in the treatment of patients with severe Buerger's disease. *Clin Appl Thromb Hemost*. 2009; 15(5):552-60.
47. Klein-Weigel P, Volz TS, Zange L, Richter J. Buerger's disease: providing integrated care. *J Multidiscip Healthc*. 2016; 9:511.
48. Cacione DG, Baptista-Silva JC, Macedo CR. Pharmacological treatment for Buerger's disease. *Cochrane Database Syst Rev*. 2016; 5(5):CD011033.
49. Sen I, Agarwal S, Tharyan P, Forster R. Lumbar sympathectomy versus prostanoids for critical limb ischaemia due to non-reconstructable peripheral arterial disease. *Cochrane Database Syst Rev*. 2018; 4(4):CD009366.
50. Sasajima T, Kubo Y, Inaba M, Goh K, Azuma N. Role of infrainguinal bypass in Buerger's disease: an eighteen-year experience. *Eur J Vasc Endovasc Surg*. 1997; 13(2):186-92.
51. Hafezi S, Modaghegh M. Sympathetic Denervation Using Endovascular Radiofrequency Ablation in Patients with Thromboangiitis Obliterans (Buerger's Disease). *Ann Vasc Surg*. 2017; 45:336.
52. Cacione DG, Moreno DH, Nakano LC, Baptista-Silva JC. Surgical sympathectomy for Buerger's disease. *JRSM Open*. 2017; 8(8):2054270417717666.
53. Sayin A, Bozkurt A, Tüzün H, Vural F, Erdog G, Özer M. Surgical treatment of Buerger's disease: experience with 216 patients. *Cardiovasc Surg*. 1993; 1(4):377-80.
54. Lee CY, Choi K, Kwon H, Ko G-Y, Han Y, Kwon T-W, et al. Outcomes of endovascular treatment versus bypass surgery for critical limb ischemia in patients with thromboangiitis obliterans. *PLoS One*. 2018; 13(10):e0205305.
55. Jiménez-Gallo D, Albarrán-Planelles C, Arjona-Aguilera C, Blanco-Sánchez G, Rodríguez-Mateos ME, Linares-Barrios M. Treatment of thromboangiitis obliterans (Buerger's disease) with high-potency vasodilators. *Dermatol Ther*. 2015; 28(3):135-9.
56. Martin-Rufino JD, Lozano FS, Redondo AM, Villaron EM, Rueda R, Fernandez-Samos R, et al. Sequential intravenous allogeneic mesenchymal stromal cells as a potential treatment for thromboangiitis obliterans (Buerger's disease). *Stem Cell Res Ther*. 2018; 9(1):1-6.
57. Lim J-H, Byeon Y-E, Ryu H-H, Jeong Y-H, Lee Y-W, Kim WH, et al. Transplantation of canine umbilical cord blood-derived mesenchymal stem cells in experimentally induced spinal cord injured dogs. *J Vet Sci*. 2007; 8(3):275-82.
58. Yusoff FM, Kajikawa M, Takaeko Y, Kishimoto S, Hashimoto H, Maruhashi T, et al. Long-term clinical outcomes of autologous bone marrow mononuclear cell implantation in patients with severe thromboangiitis obliterans. *Circ J*. 2020; 84(4):650-5.
59. Jeong ST, Ra JC. Treatment of Buerger's disease (Thromboangiitis obliterans) with autologous adipose tissue-derived mesenchymal stem cell: Report of three cases. *F1000Res*. 2019; 8(2016):2016.
60. Shigematsu H, Yasuda K, Sasajima T, Takano T, Miyata T, Ohta T, et al. Transfection of human HGF plasmid DNA improves limb salvage in Buerger's disease patients with critical limb ischemia. *Int Angiol*. 2011; 30(2):140-9.
61. Isner JM, Baumgartner I, Rauh G, Schainfeld R, Blair R, Manor O, et al. Treatment of thromboangiitis obliterans (Buerger's disease) by intramuscular gene transfer of vascular endothelial growth factor: preliminary clinical results. *J Vasc Surg*. 1998; 28(6):964-75.