

Concomitant radiofrequency ablation and foam-sclerotherapy of varicose veins; a design with novel plots

Hossein Hemmati¹, Kambiz Faridmarandi¹, Yousof Shahrouzvand¹, Sara Ramtinfar¹, Azadeh Mohammadi¹, Maral Mousavi¹

¹Razi Clinical Research Development Unit, Guilan University of Medical Sciences, Rasht, Iran

Corresponding author: Dr. Hossein Hemmati

Razi hospital, Sardar Jangal Street, Rasht, Guilan province, Iran. Postal code: 414489565

Email: drhossein.hemmati@gmail.com; Tel/Fax: +98 13 33542460; https://orcid.org/0000-0002-9393-5782

Received: 2020, September, 12 Accepted: 2020, 2021, January, 02

Abstract

To evaluate the outcome of radiofrequency ablation (RFA) procedure concomitantly performed with ultrasonography guided foam sclerotherapy (UGFS) in patients with varicose veins. To assess the effect of diameter of greater saphenous vein (GSV), distance from saphenofemoral junction (SFJ) and catheter entry site on outcome. Patients with symptomatic varicose veins underwent RFA concomitant with UGFS. Three follow up sessions were scheduled to evaluate patients in terms of recanalization and non-occlusion and complication rates. Combined procedures were used for 350 patients and 375 legs with varicosities. After 3 months of follow up, none of the patients showed any evidence of reflux. No reflux was observed in 99.2%, 97.8%, and 96.3% of patients at 6, 9 and 12 months. The occlusion probability was 99.7%, 99.4%, 99.4%, 99.4% at 3, 6, 9 and 12 months. Three legs (0.8%) were recognized as cases with proximal deep vein thrombosis (DVT). The relationship between three measured variants and occlusion probability or recanalization rate was not statistically significant. Treating the varicose veins concomitantly with RFA and UGFS could result in excellent rate of occlusion and very low rate of recanalization and complications.

Keywords: Radio frequency ablation, Foam sclerotherapy, Varicose veins

Introduction

High ligation and surgical stripping of saphenous vein, as the gold standard of varicose veins, has been progressively replaced by minimally invasive techniques. An endovenous thermal ablation technique using radiofrequency has been introduced in 1999. The widespread use of the radiofrequency ablation (RFA) was speeded up by the high rates of efficacy and safety. Occlusion rates of 92- 98% and minimal procedure-related complications placed the RFA with the new generation catheter; closure FAST; superior to open surgical techniques and comparable to endovascular laser procedures. The safety and efficacy of ultrasound guided foam sclerotherapy (UGFS) has been proved and it has been applied as an alternative option to phlebectomy for treatment of remaining varicosities after the ablating of refluxing truncal and perforating veins [1-6].

Compared to the use of endovascular laser ablation techniques, post procedure pain and measures related to quality of life have shown an improvement with RFA [7-12]. Recent studies have

demonstrated diversity in performing the different steps of technique; mostly related to the part of injecting the tumescence fluid [13-15].

Few studies, using endovascular thermal ablation methods concomitant with foam-sclerotherapy or phlebectomy has shown to be feasible and beneficial; resulting in lower rates of recanalization [16, 17]. The aim of this study was to report the experience with concomitant use of Closure FAST RFA and foam-sclerotherapy and to introduce the results of performing RFA with novel plots.

Materials and Methods

This trial performed after the approval of Guilan university ethics committees and gathering informed consents from all the patients. All of patients with varicose veins and clinical category of CEAP grade 2-6 (Clinical-Etiology-Anatomy-Pathophysiology) who referred to clinic of vascular surgery were enrolled between 2010-2013. Saphenofemoral incompetency has been established using duplex ultrasound for all the cases before the

procedure. Patients with inappropriate access point in whom vein segments were less than 7 cm were excluded and a number of 350 patients were entered the study. Most of the patients (325) underwent the procedure for one leg and 25 of them were patients with varicose veins of both legs.

A total number of 375 legs underwent the procedures. All of the patients were treated by Closure FAST RFA concomitant along with the UGFS. All the procedures performed in an outpatient setting at an ambulatory surgery center. Before the procedure venous tributaries were evaluated and mapped with duplex ultrasound. We have not used any type of sedation or anticoagulation for patients. After sterile preparation and draping, the Closure FAST catheter was inserted percutaneously through a 7F vascular sheath using the Seldinger technique. We considered 5cm below the knee up to the thigh as the field of sheath insertion. The access point considered as the most distal part of reflux in which the catheterization was possible. The sheath was introduced to saphenous vein whenever it was suitable through this field, then the probe was inserted and guided toward the sapheno-femoral junction.

Under the guidance of ultrasonography, when the catheter placed 15-20 mm away from the sapheno-femoral junction, the tumescent containing Saline solution and Xylocaine was injected. In contrast to former descriptions of the technique, we confirmed the final position of probe with duplex ultrasound after and not prior to the injection of tumescence fluid [18]. We believe the described compression effect of tumescent on vein could lead to malposition of probe and carries the risk of heat induced thrombosis in a case of displaced forward probe or recanalization in a case of displaced downward probe [19].

After positioning the tip of RF probe 15-20 mm away from the sapheno-femoral junction, the catheter was inserted over the guide wire positioned. In order to empty the veins, after the injection of tumescent anesthesia the patient was placed in Trendelenberg position. In contradiction to former technical guidelines, we used the maximum allowed cycles; three bursts of radiofrequency energy for the first segment and two bursts for the each of rest segments. We believe applying more allowed cycles might result in better outcome. After successful ablation of targeted veins with radiofrequency, residual varicose veins managed with sclerotherapy using 5-10 ml of Sodium Tetracycl Sulfate foam under the guide of sonography.

Applying the compression stocking was initiated immediately after the end of procedure. All the patients ambulated normally and left the clinic in half an hour after the procedure. Wearing the compression stockings recommended to all of patients for two weeks. Patients were allowed to get back to their routine work after 24-48 hours and they were advised to avoid heavy exercises for two weeks.

A follow up program was scheduled for all of patients with three sessions after 1month, 6month and 12 months of procedure. Duplex ultrasound was performed on each session to assess the occlusion, and recanalization rates [20]. Any complications including nerve injury, pigmentation, thrombophlebitis and deep vein thrombosis (DVT) were assessed and recorded.

Statistical analysis was performed using SPSS version 21. Kaplan-Meier analysis was applied to describe the recanalization rate and non-occlusion rate during the follow up period [18]. To investigate the effect of diameter of saphenous vein and the distance between the site of fist burst and saphenofemoral junction (SFJ) on recanalization rate and non-occlusion rate over time, we used Cox Regression model. Tarone-Ware test used to determine whether there were statistically significant differences in the recanalization and non-occlusion distributions between the groups based on entry site for catheter.

Results

Three hundred seventy five legs concomitantly underwent RFA with UGFS. All of procedures performed by the same endovascular surgeon in an outpatient setting.

The mean age of study population was 47 ± 11.9 . One hundred and sixty five (47%) patients were female and 185 (53%) were male. The frequency of patients based on CEAP classification has shown in Table 1. The mean preoperative diameter of saphenous vein which defined as the maximum transverse diameter of the first 10 cm of greater saphenous vein (GSV) in standing position, was 11.27 ± 3.24 mm and the mean distance between the site of first burst and SFJ was 15.93 ± 2.08 mm. Entry point for catheter were at the knee level in 227 legs (60.5%), above the knee in 103 legs (27.5%), below the knee in 10 legs (2.7%) and proximal of thigh in 35 legs (9.3%).

Doppler ultrasound examination was performed for all patients on follow up visits. After 3 months of follow up, none of patients showed any evidence of reflux. No reflux was observed in 99.2%, 97.8%, and

Table 1. Basic demographic features of study population

Variable	Frequency
Number of legs	375
Number of patients	350
Sex (Female/Male %)	165/185 (47%/53%)
Age(mean ± SD)	47±11.9
Preoperative diameter of Saphenous vein (mean ±SD)	11.27±3.24 mm
Distance from SFJ	15.93±2.08 mm
Entry site for catheter	At the knee level: 227 legs (60.5%) Above the knee: 103 legs (27.5%) Below the knee: 10 legs (2.7%) Proximal of thigh: 35 legs (9.3%)
Clinical severity:	168 of 375 legs (44.8%)
Varicose veins (C2)	
Swelling (C3)	150 of 375 legs (40%)
Hyperpigmentation and/or Lipodermatosclerosis (C4)	37 of 375 legs (9.8%)
Healed ulcer (C5)	16 of 375 legs (4.2%)
Active ulcer (C6)	4 of 375 legs (1%)

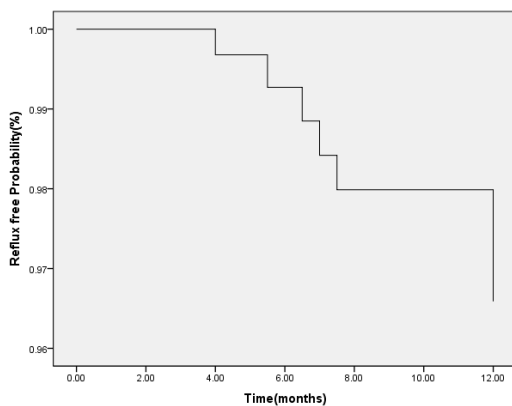


Figure1. Time to reflux analysis based on Kaplan Meier method




Figure 2. Time to flow analysis based on Kaplan Meier method

96.3% of legs at 6, 9 and 12 months. The probability of reflux was 0.8%, 2.2% and 3.7% at 6, 9 and 12 months. Standard error based on Kaplan Meier analysis was less than 2% during the study period. The mean time of having no blood flow in treated veins was 11.8±0.06 months (95%CI: 11.8-11.99) (Figure1).

There were no significant effect of the diameter of GSV on recanalization rate (p=0.341, 95%CI 0.692-1.136), and the relationship between recanalization rate and distance from SFJ on first burst has shown no statistical significance (p=0.287, 95%CI 0.906-1.399). The probability of having no

flow in treated veins was not influenced by the catheter entry site ($p=0.730$).

All legs with non-occlusion were described and plotted using the Kaplan-Meier analysis. The occlusion probability was 99.7%, 99.4%, 99.4%, 99.4% at 3, 6, 9 and 12 months. Standard error was less than 1% at all times. The mean time of having occlusion in treated veins was 11.95 ± 0.039 (95%CI: 11.9-12) (Figure 2).

The occlusion probability was not affected by any of the site of catheter entrance ($p=0.846$), diameter of GSV ($p=0.368$, 95%CI: 0.822-1.697) or distance from SFJ on first burst ($p=0.682$, 95%CI: 0.505-2.845). Evaluation the patients with sonography reported three legs (0.8%) as cases with proximal (Femoral) DVT; two of them after two weeks and one of them after one month of treatment. None of them progressed to pulmonary emboli and all of three adequately treated with anticoagulant regimens. There were 202 legs with hyperpigmentation at the site of sclerotherapy after two weeks (53.8%), 124 cases with hyperpigmentation after 3 months (33%), and 38 legs after 12 months of follow up. No cases of procedure -related deaths or hospitalization were recorded. We had no cases with hyperpigmentation at the site of RFA. No patient developed hematoma, skin necrosis, infection, nerve injury, vessel perforation, skin burn or phlebitis.

Discussion

This study revealed an excellent success rate of RFA procedure concomitantly performed with UGFS in a cohort of patients with different classes of CVI based on CEAP criteria. Very low rates of recanalization and non-occlusion and low rates of DVT occurred during the study, leave no trepidation about the efficacy and safety of using both procedures at the same time and imply the cost effectiveness of the project. This survey evaluated factors like diameter of saphenous vein and the entrance site of catheter and reported all of them as variables with no effect on recanalization or non-occlusion rates.

Searching publications we could find two similar studies reporting the combined use of RFA and UGFS in Klippel-Trenaunay syndrome patients [21, 22]. In one of the studies they have reported remarkable relief of symptoms with no procedure related complications after 6 months of follow up [21]. Another study reported excellent occlusion rates (88%) after 5 years of follow up [21, 22]. Proebstle et al conducted a prospective, multicenter study on 256 legs with varicosities of GSV with or

without calf tributary involvement. They treated 147 legs with Radiofrequency segmental thermal ablation (RSTA) combined with phlebectomy and 31 legs (12.1%) with RFA combined with UGFS (13 legs: 12.1%). They reported the probability of occlusion as 99.7%, 98.6%, 96.3% ,and the probability of having no reflux as 99.7%, 99.3%, 99% at 3, 6 and 12 months [18]. We reported similar results, although the procedure we applied was RFA concomitant with UGFS for all of study population.

Yilmaz et al reported the outcome of endovascular laser ablation and UGFS in 944 legs. In this retrospective study the mean follow up time was 19 ± 6 months with 203 legs showing a level of reflux and recanalization of 16 legs. They reported 1.4% of major complications including skin necrosis and calf vein thrombosis. DVT incidence reported as 0.5% [16]. We reported 0.8% of DVT and no cases of skin necrosis. Different size of study population and design of study, using different procedures, applying Kaplan Meier survival analysis, could rationalize the different results.

Compared to studies performing RFA without any other procedures, we reported higher rates of occlusion and lower rates of recanalization at any time interval [9, 10, 23] .

We believe the higher rates of occlusion and lower rates of recanalization in our study might be partly related to the concomitant use of procedures, although using the maximum allowed cycles with RFA probe and verification of probe position after the injection of tumescent should be taken into account.

New meta-analysis focusing on the venous thromboembolism (VTE) as a life-threatening complication of endovascular ablation methods or sclerotherapy have been reported an incidence of less than 2% of DVT related to each of procedures without any significant difference between methods [24, 25]. However there are studies reporting no cases of DVT as a consequence of RFA [9, 18]. The incidence we reported (0.8%) is as same as reported by meta-analytic studies of RFA complications [24, 25]. Implementation of two procedures with DVT in their complication list, and using no anticoagulation before the procedure, could be related to the incidence of DVT we have reported, although there could be other predisposing parameters we have not assessed [26].

Many studies have measured different patient factors in relation to recanalization and non-occlusion rate. In some studies, diameter of the vein at SFJ has shown no correlation to anatomical failure

[10, 27]. A retrospective study of 364 patients who treated with endovascular laser, reported a significant effect of size of vein ($p=0.042$) and the site of entry for catheter ($p= 0.085$) on recanalization rates [28].

In regard to the small population we reported as failure rate, concluding about the effect of correlated factors is not possible and demands larger populations for study.

Treating varicose veins using combined procedures in one session could lead to save of time and shortening the post procedure period needed for wearing hosiery and patient recovery. According to supplies and equipment that could be used for both procedures, merging multiple sessions into one, impose a lower financial burden on patients. Venous stasis in tributaries as a side effect after RFA of GSV could result in superficial venous thrombosis and even DVT, which leads to postponement of next treatment session, extends the period of treatment, results in undesired cosmetic appearance and brings patient dissatisfaction [29]. Performing concomitant sclerotherapy for remaining tributaries reduces the stasis and thus the incidence of superficial thrombophlebitis, providing better cosmetic results in a shorter duration of treatment period [30]. Based on ASVAL theory stasis of peripheral venous branches after the ablation of GSV by RFA, could be introduced as a predisposing factor for procedure failure [31]. We believe concomitant treatment of peripheral venous network at the same session of ablating the GSV, decreases the risk of recanalization by abolition of venous flow distal to the SFJ [32].

There were a number of limitations to this study. In regard to very low failure rates, evaluating the correlation of variants to recanalization and non-occlusion rates was not possible. Another limitation is providing outcome only based on ultrasound reports and no presentation of clinical outcomes based on CEAP or VCSS scores [33].

Clinical report of outcome and progression course is especially important in patients with recanalization. More than 40% of patients with recanalization show resolution of symptoms and need no subsequent procedure [23, 27]. Considering the aim of our study which was defined as assessment of efficacy, we preferred to report the radiological outcome at first .post procedure clinical assessment should be evaluated in further trials with large study populations.

We believe concomitant ablation of GSV with RFA and peripheral venous network with UGFS, delivery of maximum allowed cycles with RFA

probe, and verification of probe position after the injection of tumescent are parts of a novel plot for treatment of varicose veins and could be applied as an effective technique for treatment of varicose veins.

Acknowledgments

The authors thank Razi clinical Research Development Unit and all the patients who participated in this study.

Author contribution

HH, KF: designing the study, reading and approving the final version of the manuscript before submission. YS: collecting the data, writing the first draft, reading and approving the final version of the manuscript before submission. AM: data analysis, reading and approving the final version of the manuscript before submission. SR: editing the manuscript, reading and approving the final version of the manuscript before submission

Conflict of Interest

Authors declare no conflicts of interest.

Ethical Declaration

This trial performed after the approval of Guilan university ethics committees and gathering informed consents from all the patients. Ethics approval for this study was obtained from Guilan University of Medical Sciences Research Ethics Committees (ethical code: IR.GUMS.1394.580).

Financial Support

There was no source of funding.

References

1. Lin F, Zhang S, Sun Y, Ren S, Liu P. The management of varicose veins. *Int Surg.* 2015;100(1):185-9.
2. Gloviczki P, Gloviczki ML. Guidelines for the management of varicose veins. *Phlebology.* 2012;27 Suppl 1:2-9.
3. Coleridge Smith P. Sclerotherapy and foam sclerotherapy for varicose veins. *Phlebology.* 2009;24(6):260-9.
4. Myers KA, Roberts S. Evaluation of published reports of foam sclerotherapy: what do we know conclusively? *Phlebology.* 2009;24(6):275-80.
5. Morrison N. Ultrasound-guided foam sclerotherapy: safety and efficacy. *Phlebology.* 2009;24(6):239.
6. Nesbitt C, Bedenis R, Bhattacharya V, Stansby G. Endovenous ablation (radiofrequency and laser) and foam sclerotherapy versus open surgery for great saphenous vein varices. *Cochrane Database Syst Rev.* 2014(7):Cd005624.
7. Garcia-Madrid C, Pastor Manrique JO, Gomez-Blasco F, Sala Planell E. Update on endovenous radio-frequency

- closure ablation of varicose veins. *Annals of vascular surgery*. 2012;26(2):281-91.
8. Dietzek AM. Endovenous radiofrequency ablation for the treatment of varicose veins. *Vascular*. 2007;15(5):255-61.
9. Garcia-Madrid C, Pastor Manrique JO, Gomez Blasco F, Sala Planell E. [New advances in the treatment of varicose veins: endovenous radiofrequency VNUS Closure(R)]. *Cirugia espanola*. 2011;89(7):420-6.
10. Avery J, Kumar K, Thakur V, Thakur A. Radiofrequency ablation as first-line treatment of varicose veins. *Am Surg*. 2014;80(3):231-5.
11. Roth SM. Endovenous radiofrequency ablation of superficial and perforator veins. *Surg Clin North Am*. 2007;87(5):1267-84, xii.
12. Rasmussen LH, Lawaetz M, Bjoern L, Vennits B, Blemings A, Eklof B. Randomized clinical trial comparing endovenous laser ablation, radiofrequency ablation, foam sclerotherapy and surgical stripping for great saphenous varicose veins. *Br J Surg*. 2011;98(8):1079-87.
13. Tolva VS, Cireni LV, Bianchi PG, Lombardo A, Keller GC, Casana RM. Radiofrequency ablation of the great saphenous vein with the ClosureFAST procedure: mid-term experience on 400 patients from a single centre. *Surg Today*. 2013;43(7):741-4.
14. Korkmaz K, Yener AU, Gedik HS, Budak AB, Yener O, Genc SB, et al. Tumescentless endovenous radiofrequency ablation with local hypothermia and compression technique. *Cardiovasc J Afr*. 2013;24(8):313-7.
15. Kendler M, Simon JC, Wetzig T. Local anesthesia with lidocaine and prilocaine, using the tumescent technique, for the radiofrequency ablation of lower extremity varicose veins. *Int J Dermatol*. 2013;52(6):739-44.
16. Yilmaz S, Ceken K, Alparlan A, Durmaz S, Sindel T. Endovenous laser ablation and concomitant foam sclerotherapy: experience in 504 patients. *Cardiovasc Intervent Radiol*. 2012;35(6):1403-7.
17. Harlander-Locke M, Jimenez JC, Lawrence PF, Derubertis BG, Rigberg DA, Gelabert HA. Endovenous ablation with concomitant phlebectomy is a safe and effective method of treatment for symptomatic patients with axial reflux and large incompetent tributaries. *Journal of vascular surgery*. 2013;58(1):166-72.
18. Proebstle TM, Vago B, Alm J, Gockeritz O, Lebard C, Pichot O. Treatment of the incompetent great saphenous vein by endovenous radiofrequency powered segmental thermal ablation: first clinical experience. *Journal of vascular surgery*. 2008;47(1):151-6.
19. Chait J, Kibrik P, Alsheekh A, Ostrozhynskyy Y, Marks N, Rajae S, et al. Radiofrequency Ablation Increases the Incidence of Endothermal Heat-Induced Thrombosis. *Annals of vascular surgery*. 2020;62:263-7.
20. Eklof B, Perrin M, Delis KT, Rutherford RB, Gloviczki P. Updated terminology of chronic venous disorders: the VEIN-TERM transatlantic interdisciplinary consensus document. *Journal of vascular surgery*. 2009;49(2):498-501.
21. Sermsathanasawadi N, Hongku K, Wongwanit C, Ruangsetakit C, Chinsakchai K, Mutirangura P. Endovenous radiofrequency thermal ablation and ultrasound-guided foam sclerotherapy in treatment of klippel-trenaunay syndrome. *Ann Vasc Dis*. 2014;7(1):52-5.
22. Harrison C, Holdstock J, Price B, Whiteley M. Endovenous radiofrequency ablation and combined foam sclerotherapy treatment of multiple refluxing perforator veins in a Klippel-Trenaunay syndrome patient. *Phlebology*. 2014;29(10):698-700.
23. Bunnell AP, Zaidi S, Eidson JL, 3rd, Bohannon WT, Atkins MD, Jr., Bush RL. Factors associated with saphenous vein recanalization after endothermal ablation. *Annals of vascular surgery*. 2015;29(2):322-7.
24. Dermody M, Schul MW, O'Donnell TF. Thromboembolic complications of endovenous thermal ablation and foam sclerotherapy in the treatment of great saphenous vein insufficiency. *Phlebology*. 2015;30(5):357-64.
25. Benarroch-Gampel J, Sheffield KM, Boyd CA, Riall TS, Killewich LA. Analysis of venous thromboembolic events after saphenous ablation. *Journal of vascular surgery Venous and lymphatic disorders*. 2013;1(1):26-32.
26. Jacobs CE, Pinzon MM, Orozco J, Hunt PJ, Rivera A, McCarthy WJ. Deep venous thrombosis after saphenous endovenous radiofrequency ablation: is it predictable? *Annals of vascular surgery*. 2014;28(3):679-85.
27. Merchant RF, Pichot O. Long-term outcomes of endovenous radiofrequency obliteration of saphenous reflux as a treatment for superficial venous insufficiency. *Journal of vascular surgery*. 2005;42(3):502-9; discussion 9.
28. Knipp BS, Blackburn SA, Bloom JR, Fellows E, Laforge W, Pfeifer JR, et al. Endovenous laser ablation: venous outcomes and thrombotic complications are independent of the presence of deep venous insufficiency. *Journal of vascular surgery*. 2008;48(6):1538-45.
29. Hingorani AP, Ascher E, Markevich N, Schutzer RW, Kallakuri S, Hou A, et al. Deep venous thrombosis after radiofrequency ablation of greater saphenous vein: a word of caution. *Journal of vascular surgery*. 2004;40(3):500-4.
30. Endovascular laser therapy for varicose veins: an evidence-based analysis. Ontario health technology assessment series. 2010;10(6):1-92.
31. Welch HJ. Endovenous ablation of the great saphenous vein may avert phlebectomy for branch varicose veins. *Journal of vascular surgery*. 2006;44(3):601-5.
32. Atasoy MM, Gumus B, Caymaz I, Oguzkurt L. Targeted endovenous treatment of Giacomini vein insufficiency-associated varicose disease: considering the reflux patterns. *Diagnostic and interventional radiology (Ankara, Turkey)*. 2014;20(6):481-6.
33. Kundu S, Lurie F, Millward SF, Padberg F, Jr., Vedantham S, Elias S, et al. Recommended reporting standards for endovenous ablation for the treatment of venous insufficiency: joint statement of The American Venous Forum and The Society of Interventional Radiology. *Journal of vascular surgery*. 2007;46(3):582-9.